

PRESIDENTIAL ADDRESS

A CASE REPORT AND MISCELLANEOUS COMMENTS

Brian Blades, M.D., Washington, D. C.

MY FIRST and pleasant obligation is to express profound appreciation to the members of The American Association for Thoracic Surgery. And of equal importance, to thank the Officers and committee members whose efforts determine the success or failure of our meeting. Particular gratitude is deserved by the Secretary, Dr. Hiram Langston, and Miss Ada Hanvey, Administrative Assistant.

The honor of being President of this Association is impossible to define. The endeavors of those whom I have just cited have made most of the duties and responsibilities of the office easy. There is, however, one notable exception, the preparation and presentation of the presidential address.

Mild plagiarism was first considered. A careful review of my predecessors' contributions, however, made this impractical. Their subjects have consisted of dissertations on philosophical, educational, and historical matters or reports of brilliant surgical achievements or research endeavors. It became apparent I had neither information nor the ability to imitate their examples.

In desperation I have decided to present a case report as the principal feature of this address.

The unusual history, methods of diagnosis and, finally, the surgical management will, I hope, justify the review of a clinical problem in a Presidential Address.

Following the case report there will be a few miscellaneous and probably confusing comments.

From the Department of Surgery, The George Washington University, Washington, D. C.
Presented at the Thirty-eighth Annual Meeting of The American Association for Thoracic Surgery at Boston, Mass., May 16-18, 1958.

CASE REPORT*
BARNES HOSPITAL

History No. 37532
 Name Gilmore, James Lee (Dr.) Nee _____
 Address 1331 Inverness Pittsburg Pennsylvania
 Age (1st Admission) 49 Years Married, Single, Divorced Separated
 Sex Male Race White Nativity Pennsylvania Occupation Physician
 Nearest Relative or Friend Marjorie Gilmore How Related Wife
 Address Same
 Family Physician _____
 Address _____
 Recommending Physician Dr. W. T. Mitchell, Jr. O.P.D. No. _____
 Address Pittsburg Pennsylvania
 Staff Physician Dr. Graham Dr. Arbuckle Dr. Singer
 Remarks _____

*The case report is a facsimile of the original records including misspelled words.

ADM. DATE	SERV.	DISCH. DATE	DIAGNOSIS & OPERATION	CONDITION AT DISCHARGE
27 Feb 33	Surg Med	5 Mar 33	Tumor of Bronchus, Uncertified. (Lt. upper lobe) Artificial Pneumothorax. (Carcinoma?) 3-1-33 Bronchoscopy.	Not Improved
9 Mar 33	Surg	9 Mar 33	Tumor of Bronchus, Uncertified. (Carcinoma?)	Not Treated
13 Mar 33	Med Surg	24 Mar 33	Carcinoma of Bronchus. 3-14-33 Bronchoscopy. Excision of Tissue of Bronchus for Diagnosis. 3-21-33 Bronchoscopy.	Not Treated
4 Apr 33	Surg	18 Jun 33	Carcinoma of Bronchus. (Lt. upper lobe) Carcinoma of Lung. (Squamous cell) 4-5-33 Pneumectomy. (Total) (Left) Blood Transfusion. Thoracoplasty. (Partial) (Left) 4-19-33 Thoracostomy. (Closed drainage) (Left) 5-13-33 Thoracostomy. (for empyema) 5-22-33 Thoracoplasty. (Partial) (Left)	Improved

Abstract of the record of Dr. James L. Gilmore. Age 48 yrs.

Admitted	Discharged
2-27-33	3-5-33
3-9-33	3-9-33
3-13-33	3-24-33
4-4-33	6-18-33

Patient enters hospital with a history of:

1. Repeated attacks of cough and fever with pain in the chest.
2. General lassitude.
3. Easily fatigued.
4. Loss of weight and inability to gain weight.

} 7 months
duration.

In January 1929 patient developed pneumonia of the right lower lobe. It spread from this location and involved the entire lung. Convalescence was delayed for several weeks and terminated by his "raising some pus."

In July 1932 he experienced a general malaise with chilly sensation and a fever of 104. Nothing found on P. X. WBC. 17,000. On Aug. 11th an x-ray revealed a fan-shaped shadow with the base outward, in the region of the left axilla. By Aug. 20th his symptoms had subsided and the x-ray shadow had become smaller. On Oct. 7th he experienced a repetition of his former symptoms with return of the former x-ray shadow. This subsided in a few days only to recur again about Oct. 20th. At this time there was some dullness and a diagnosis of (interlobar empyema) lung abscess was made. On attempting to aspirate it (Dec. 5, 1932) a pneumothorax developed, subsequent to which his symptoms improved. He experienced some pain in the left chest following production of pneumothorax (not much pain and no bloody sputum at any time). The pneumothorax was continued and was improved until 10 days before admission (2-17-33) when he had a recurrence of fever and discomfort, etc. Examination revealed a man of medium build with suggestion of loss of weight and having a pale pasty complexion. Did not look acutely ill. The left chest moved less than the right and B. S. were diminished or absent. X-rays of the chest showed the left upper lobe atelectatic with pneumothorax present. (The lower lobe seemed fully expanded and adherent to the chest wall). RBC. 4,800,000, WBC. 11,500, HB. 85%.

In view of the patient's history, PX., and x-ray findings, a tentative diagnosis of bronchial obstruction by a tumor was made.

Bronchography substantiated the diagnosis of bronchial obstruction of the left upper lobe.

Bronchoscopy 3-1-33 revealed tissue not unlike the appearance of granulation tissue, closing off the lt. upper bronchus. Bronchoscopy repeated on 3-14-33 and 3-21-33. Biopsy taken revealed squamous cell carcinoma of the bronchus.

Patient took microscopic slides to home pathologist to have verified.

Patient was readmitted 4-4-33 for lobectomy. At the operation (4-5-33) the tumor and suppurative process was found such that it was necessary to remove the entire left lung. Many adhesions made this somewhat difficult. Seven ribs were also removed, 3 to 9 inclusively. Left the operating room in good condition: (had received glucose-acacia and some blood). Closed drainage yielded several (800 to 1000 cc.) of serosanguinous exudate for 48 hours. There was little P.O. reaction except for some dyspnea especially on exertion. Considerable deep-seated pain was experienced at times but was fairly well controlled. Some infection of the unobliterated portion of the left chest occurred on the 8th or 9th P.O. day which was drained by a stab wound posteriorly. This failed to function after 2 weeks (during which time patient was being prepared for removal of the remaining 1st and 2nd ribs to obliterate the remaining space) so a 2nd drain was placed

anteriorly through the 1st interspace. The 1st and 2nd ribs were removed on 5-22-33, with little post-operative reaction. His pain then completely subsided and within 3 weeks all wounds were healed. His strength gradually increased, as well as the use of his left arm. He gained in weight and his color improved remarkably. Appetite was good and on discharge, 6-18-33, he was looking quite healthy, much better than he had for many months previously. His only complaint was some dyspnea on exertion and this was not marked. His respiratory function improved much after his heart had become compensated to his being up and about. He had been walking about for 2 weeks at time of discharge from hospital. Vital capacity on admission 3,500; at discharge 1,650. At time of discharge his blood showed 5,100,000 RBC., 8,500 WBC., and 90% HB. On discharge, his ECG. was practically normal.

Weight on admission 4-4-33 145 lbs.. On May 21, 1933, his weight was 130 lbs.. On June 14, 121½ lbs., June 18, 122½ lbs., June 28, 126 lbs..

Operative Report

Anesthetic Remarks: Uneventful. Pulse good volume. Color good. Glucose given when B.P. fell. Pt. responded at completion of operation. Blood transfusion was given. Dictation: Dr. Graham.

An incision was made over the 6th rib; the rib was removed from the transverse process to the anterior axillary line. The 7th rib was also removed in the same way and the intercostal bundle was excised. The pleura was opened and the upper lobe was found to be atelectatic. Several masses could be felt within it suggestive of infiltration with carcinoma. Although the apex of the lung was free from adhesions, there were many other adhesions between the lung and the chest wall. There were particularly dense adhesions between the upper lobe and pericardium, and also posteriorly between the upper lobe and the parietal pleura. The lower lobe was adherent everywhere to the chest wall. In the upper part of the upper lobe several firm nodules were felt which were suggestive of carcinomatous metastases. In attempting to separate the upper lobe from the lower lobe, it was found that the interlobar fissure was not fully developed. There were also some nodules in the upper part of the lower lobe which were suspicious of carcinomatous involvement. It was felt that not only would it be very difficult to remove the upper lobe alone, but also that in doing so some of the cancer would be left behind. Consequently it was decided to remove the entire left lung. After separating the adhesions, most of which required clamping and cutting followed by ligation, the pedicle was freed and a small catheter was tightly secured around it. It seemed preferable to use the soft pressure of a rubber catheter rather than a crushing clamp for this purpose, in order to preserve the blood supply as much as possible to the end of the stump of the bronchus. The idea behind this was to encourage healing of the bronchial stump as much as possible. Distal to the catheter two clamps were placed on the entire pedicle and an incision was made between them thereby cutting away the entire lung. After cutting away the lung, the open stump of the bronchus was cauterized thoroughly with the actual cautery and then swabbed with 25% silver nitrate solution. The stump was then transfixed with a needle carrying a double thread of #2 chromic catgut. This was tied securely around the whole pedicle. Another double ligature of #2 chromic catgut was placed in a position slightly distal to the first ligature, and finally a third ligature of the same sort was applied. The catheter was then removed and no bleeding from the stump occurred. The open end of the stump of the bronchus was slightly less than one inch from the bifurcation of the trachea. The aorta was plainly visible immediately posterior to the stump of the left bronchus. Because the entire lung had been removed there was no tissue available for covering over the stump of the bronchus. Two enlarged mediastinal glands, which could be seen immediately below the bifurcation of the trachea, were removed for microscopic examination. These, however, seemed soft and evidently did not contain any cancer. Because the patient's condition seemed excellent, and because it was felt desirable to obliterate the pleural space as much as possible, additional ribs were removed

from the transverse processes to the anterior axillary line. The ribs removed were the 4th, 5th, 6th, 7th, 8th, 9th and 10th. Thru a small stab wound a small catheter was inserted below the line of incision and carried into the pleura cavity just below the stump of the pedicle. This catheter fitted tightly so that no leakage of air at all occurred around it. The wound was then closed in layers and it was noted that the soft tissues collapsed readily into the pleural cavity. No attempt was made to suture the parietal pleura together. The 6th and 7th muscle bundles had been removed in order to give exposure, but the rest of the muscle bundles were not cut away. The patient was given a blood transfusion in the operating room and left the operating room with blood pressure and pulse the same as they had been at the beginning of the operation. The rubber catheter was connected with a longer rubber tube which was brought down to the level of some boric acid solution in a bottle in order to give air tight drainage.

SURGICAL PATHOLOGY BARNES HOSPITAL

Name	Gilmore, Dr. J.L.	Register No.	89475	Age	48
Address		Ward		Date	4-5-33 (11-11-48)
Surgeon	Dr. Graham	Specimen No.	21246		

Gross Pathology: (11-11-48) The gross specimen consists of the entire left lung which is received in Kaiserling fixative. The entire lower section through the entire lung at 2 to 3 cm. intervals has been made. There is a tumor mass ulcerating into the upper lobe bronchus near the hilum which on cut section appears to be well delineated and measures 3 cm. in its greatest diameter. Distal to this tumor in the upper lobe there are numerous pinpoint abscesses in the lung parenchyma. Over the posterolateral apical region of the upper lobe there is a markedly thickened pleura which appears to have a portion of the parietal pleura attached to it. The lower lobe appears to be essentially normal without abscesses, obstruction or abnormalities of the pleural surfaces. On gross examination the superior interlobar bronchial node which is immediately adjacent to the tumor appears to be directly involved in the process. There are several other nodes about the upper lobe bronchus which do not appear to be involved in the tumor process. Several small nodes about the lower lobe bronchus are likewise negative grossly. Many black and white and colored photographs were taken of the fixed gross specimen. The following additional sections are taken.

A_x—a section of the tumor to show its entire extent

A—4 to 5 additional sections of the tumor

B₁—6 lymph nodes from about the upper lobe bronchus

B₂—a section from the thickened pleural surface at the posterior apex of the upper lobe

D₁—3 nodes from about the lower lobe bronchus Jar IV (Black)

Microscopic Pathology: The surface of the tumor as it projected into the bronchus showed a fairly well differentiated pattern with numerous epithelial pearls. The tumor extended into the lung parenchyma destroying bronchial cartilage and invading contiguous lymph nodes. In the deeper areas of the neoplasm it was extremely undifferentiated with practically no keratinization and with numerous mitotic figures. In one area of the neoplasm, as it arose from the bronchus, there was squamous metaplasia and epidermoid carcinoma in situ. Further nodes, 11 in number, showed no evidence of tumor.

Diagnosis: Lung, bronchus, left, upper — Epidermoid carcinoma, grade III

Lymph nodes, regional — Epidermoid carcinoma, grade III, invasive

Lymph nodes, regional — Hyperplasia, 11/11

Lung — Bronchial pulmonary suppuration with multiple small abscesses

Lauren V. Ackerman, M.D.

It is important to note that the review of the tissue by Dr. Lauren Ackerman in 1948 established that the lesion was an invasive epidermoid carcinoma. Moreover, there was involvement of a lymph node.

Two postoperative notes by our distinguished colleague, Dr. William Adams, then a Fellow in Surgery, are worth recording.

- 4-6-33 "Patient quite comfortable unless he moves. He had no M.S. since 8 A.M. Has
3:15 not voided since operation. B.P. remaining at 120/ No cyanosis or dyspnea. Pulse
Adams steady. Drained about 800 cc through catheter during interval from 12 M yesterday
until 11 A.M. today. Little drainage since. Temp. down to 37.2° this noon. O₂ tank
to be kept in room and O₂ tent available in case of emergency."
- 4-18-33 "Patient's temp. has risen to 39.7° tonight. Pulse 134. R 32. No cyanosis.
Adams States he is having some respiratory difficulty. Coughing if attempts to lie on rt.
side or on talking. Dr. Graham notified of condition. Given Aspirin 10 gr. and
Codeine 1 gr. to lower temp."

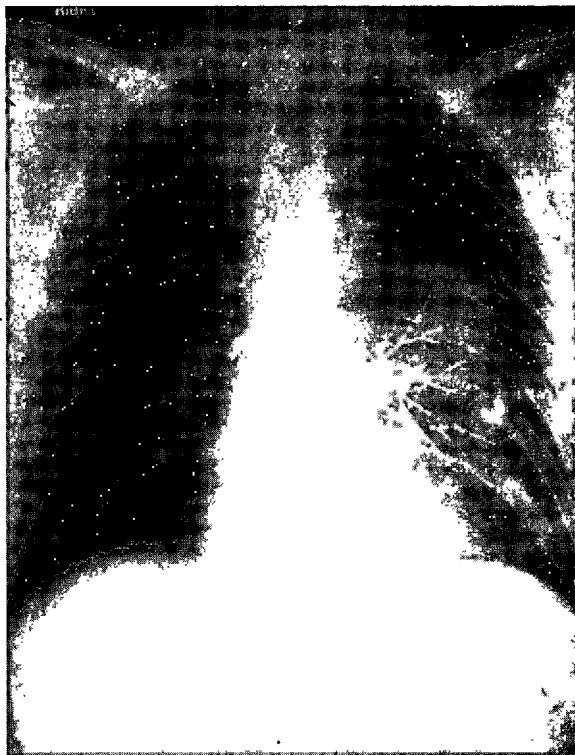

Fig. 1.—Roentgenogram showing pneumothorax and Lipiodol bronchogram. The pneumothorax was accidentally induced when a thoracentesis was performed.

- 4-19-33 "Patient's general condition about the same this A.M. except less respiratory dis-
Adams tress, less cough, and less pain since midnight. Fluoroscopy reveals similar con-
dition as that seen yesterday morning. Under general anesthesia a #14 catheter
was inserted through a trocar into cavity at level of 4th dor. vert. just medial to
scapula. 150 cc of thin redish-brown pus was removed. Open drainage established."

It appears the bronchus began to leak 13 days after the operation. Certainly no one could accuse the staff of prescribing too much medication.

A few years after the first successful pneumonectomy for carcinoma of the lung, rumors were circulated that the lesion was not really a carcinoma, but

an adenoma. The amazing longevity of misinformation has been demonstrated because to this day one occasionally hears this misstatement repeated. It is appropriate, therefore, to show a photograph of the gross specimen and the photomicrograph. (Figs. 1, 2, and 3).




Fig. 2.—The gross specimen showing a bronchogenic carcinoma in the left upper lobe.

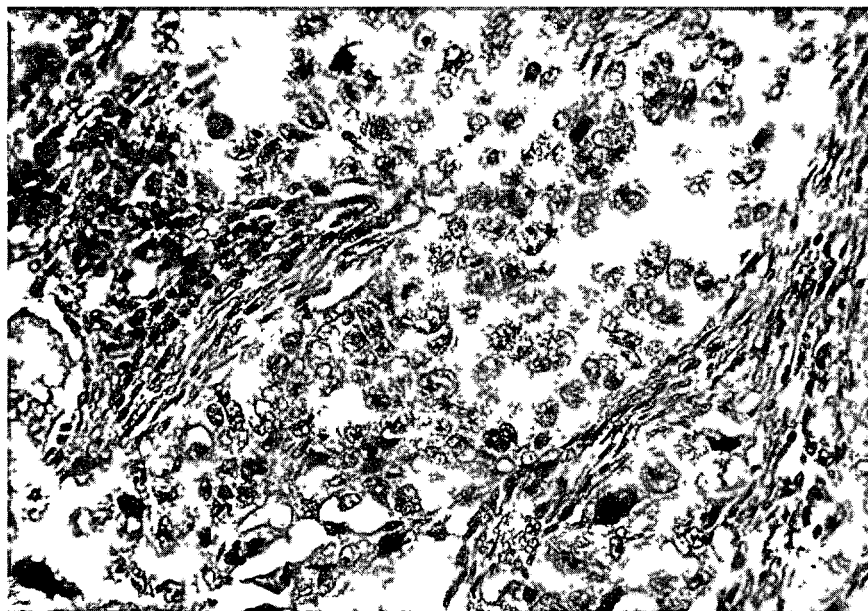


Fig. 3.—Microscopic section showing undifferentiated carcinoma.

While the patient was recovering from the pneumonectomy, thoracoplasties, and thoracostomies, the meeting of The American Association for Thoracic Surgery was held on May 9, 10, and 11, 1933. Before attending in absentia the Sixteenth Annual Meeting of the Association in Washington, D. C. it is important to conclude the case report. The patient is vigorous, living and well twenty-five years after the removal of the left lung.

THE AMERICAN ASSOCIATION FOR THORACIC SURGERY

Officers

President, George P. Muller, Philadelphia
Vice President, George J. Heuer, New York City
Secretary, Duff S. Allen, St. Louis
Treasurer, Edward D. Churchill, Boston
Editor, Evarts A. Graham, St. Louis

Council

Frederick T. Lord, Boston	Walter E. Lee, Philadelphia
T. C. Davison, Atlanta	Emile Holman, San Francisco
Edward S. Welles, Saranac Lake	

The American Association for Thoracic Surgery
Washington, D. C., May 9, 10, 11, 1933
Hotel Headquarters — The Willard Hotel

Program

Tuesday, May 9

9:00 A.M. National Museum Building.

1. Business Meeting of the Association.
2. The Results of Phrenic Nerve Operations in 225 Cases With a Discussion of the Technique of the Operations.
Dr. H. Ryerson Decker, Pittsburgh.
3. An Estimate of the Value of Phrenic Nerve Interruption for Phthisis Based on 654 Cases.
Dr. John Alexander and Dr. Lawrence Nehil, Ann Arbor.
4. Experimental Study of the Effect of Phrenicectomy on Cough.
Dr. Herbert A. Carlson, Minneapolis, Dr. Harry C. Ballon, Montreal,
Dr. Hugh M. Wilson and Dr. Evarts A. Graham, St. Louis.
5. Thoracoplasty.
Dr. E. J. O'Brien, Detroit.
6. The Operative Mortality From Thoracoplasty in Pulmonary Tuberculosis. Analysis of 6 Fatal Cases.
Dr. H. L. Beye, Iowa City.
7. A Study of 150 Cases of Thoracoplasty for Pulmonary Tuberculosis During the Past Two Years — Reflection of Technique and Results.
Dr. Pol. N. Coryllos, New York City.
8. Bronchogenic Carcinoma. Special Reference to Its Classification, Prognosis and Treatment.
Dr. Louis H. Clerf and Dr. B. L. Crawford, Philadelphia.

1:00 P.M.

1. Collapse Therapy and the Ambulatory Patient.
Dr. J. A. Myers, Minneapolis.

2. The Future Surgical Status of the Collapse Therapy Patient.
Dr. T. J. Kinsella, Oak Terrace, Minn.
3. Pneumocavernolysis in the Treatment of Pulmonary Tuberculosis With Cavitation.
Dr. Harold Neuhof, New York City.
4. Non-Penetrating Wounds of the Heart. The Cardiac Manifestations Brought About by Acute Peripheral Compression.
Dr. Claude S. Beck and Dr. Ernest Bright, Cleveland.
5. Removal of Needle From the Heart With Electrocardiographic Studies Before, During, and After Operation.
Dr. Francis Scrimger, Montreal.
6. The Diagnosis and Treatment of Encapsulated Empyemata.
Dr. W. A. Hudson, Detroit.
7. Moving picture study of the treatment of acute empyema.
Dr. Jos. Gale, Madison.
8. Moving picture study of the treatment of acute empyema.
Dr. Ralph B. Bettman, Chicago.

Wednesday, May 10

9:00 A.M.

1. Executive Meeting of the Association.
2. President's Address.
Dr. George P. Muller, Philadelphia.
3. Address on Lung Abscess and Pleural Effusion.
Dr. Marc Iselin, Paris France. (By special invitation.)
4. Pneumonectomy for Sarcoma of Lung in a Tuberculous Patient.
Dr. Howard Lilienthal, New York City.
5. Dermoids of the Mediastinum.
Dr. Carl A. Hedblom, Chicago.
6. Intrathoracic Teratomas.
Dr. S. W. Harrington, Rochester, Minn.
7. Esophagectomy for Cancer of the Upper Esophagus With Lessons Derived From an Operative Failure.
Dr. P. E. Truesdale, Fall River, Mass.
8. Experiences With Oleothorax Treatment.
Dr. John N. Hayes and Dr. Lawrason Brown, Saranac Lake.

1:00 P.M.

1. Active Contractility of the Bronchopulmonary Smooth Muscle as Demonstrated by Electrobronchographic Records.
Dr. Ethan F. Butler, Elmira, N. Y.
2. An Experimental Study of the Reactions of the Pleura to the Bacillus of Tuberculosis.
Dr. W. S. Lemon, Rochester, Minn.
3. Effects of Laparotomy and Abdominal Distention on the Lung Volume.
Dr. Edward D. Churchill, Dr. H. Beecher, Dr. H. H. Bradshaw, and
Dr. G. E. Lindskog, Boston.
4. The Treatment of Traumatic Haemothorax. An Experimental and Clinical Study.
Dr. D. C. Elkin and Dr. J. C. Sandison, Atlanta.
5. Physiological Determinants in Surgery for Relief of Cardiac Pain.
Dr. Peter Heinbecker, St. Louis.
6. The Tensile Strength of the Paralyzed Diaphragm.
Dr. Richard H. Meade, Jr., Philadelphia.
7. Extreme Compression and Cirrhosis of the Lung. A Preliminary Experimental Study.
Dr. C. M. Van Allen, Peiping, China.

8.00 P.M. PRESIDENT'S BANQUET.

Thursday, May 11

9:00 A.M.

1. Bronchiectasis.

Dr. James A. Miller, New York City.

2. Selective Surgical Collapse for Lung Abscess.

Dr. Richard H. Overholt, Boston.

3. Fixation of Chest Lesions With Subsequent Compression.

Dr. W. P. Herbert, Asheville.

4. Oidiomycosis of the Lungs.

Dr. David T. Smith, Durham, N. C.

5. Experimental Pulmonary Lesions of *Aspergillus Niger*: Superimposition of This Fungus on Experimental Pulmonary Tuberculosis.

Dr. Norman Bethune, Montreal.

6. Suture of the Lung.

Dr. Frank S. Dolley, Los Angeles.

7. Intrapleural Pneumolysis. A Critical Review.

Dr. Julian A. Moore, Asheville.

The following officers were elected for 1934:

President	Dr. George J. Heuer	New York City.
Vice President	Dr. John Alexander	Ann Arbor, Mich.
Secretary	Dr. Duff S. Allen	St. Louis, Mo.
Treasurer	Dr. Edward D. Churchill	Boston, Mass.
Editor	Dr. Evarts A. Graham	St. Louis, Mo.

The following were advanced from associate to active membership:

Dr. I. A. Bigger	Charlottesville, Va.
Dr. Alfred Blalock	Nashville, Tenn.
Dr. Peter Heinbecker	St. Louis, Mo.
Dr. W. A. Hudson	Detroit, Mich.
Dr. Richmond L. Moore	Asheville, N. C.
Dr. LeRoy S. Peters	Albuquerque, N. M.
Dr. David T. Smith	Durham, N. C.
Dr. Owen H. Wangenstein	Minneapolis, Minn.

The following were elected to associate membership:

Dr. William Adams	Chicago, Ill.
Dr. Clyde Allen	Detroit, Mich.
Dr. J. B. Amberson	New York City
Dr. Marr Bisailon	Portland, Oregon
Dr. Maurice Fisher	Rochester, N. Y.
Dr. Wallace Frank	Louisville, Ky.
Dr. Cameron Haight	Ann Arbor, Mich.
Dr. George F. Herben	Loomis, N. Y.
Dr. Chevalier Jackson, Jr.	Philadelphia, Pa.
Dr. Foster Murray	Brooklyn, N. Y.
Dr. J. W. Nixon	San Antonio, Texas
Dr. George Ornstein	New York, N. Y.
Dr. John Powers	Boston, Mass.
Dr. Leo Rigler	Minneapolis, Minn.
Dr. Willard Van Hazel	Chicago, Ill.

Of the thirty-five scientific papers presented twenty-five years ago more than a third were on various aspects of the treatment of tuberculosis. Interest in the heart was manifested by three important papers. There was only one presentation concerning bronchogenic carcinoma and two on mediastinal tumors. The subjects of empyema and lung abscess had their share of attention and it appears that one half day was devoted to experimental studies in much the same way that time is set aside for the forum in our present programs.

The esophagus rated only one paper with lessons reported from a failure of esophagectomy for carcinoma of the upper third of the esophagus. History has a strange way of repeating itself.

There were sixty-seven members present at the meeting twenty-five years ago, fifty-three active, twelve associate, and two senior members; a sharp contrast to the Thirty-Seventh Annual Meeting of the Association in Chicago at which there were more than one thousand registrations.

The meeting in Washington was held in a small lecture room of the Smithsonian Museum. The place of the meeting was determined by the Congress of American Physicians and Surgeons. This was the last time The American Association for Thoracic Surgery met as a component member of the Congress.*

The Program Committee this year received one hundred and fifty-four abstracts for consideration. Enough outstanding papers were available to fill three full programs. One might long for the good old days, but a quarter of a century ago the trials of the program committee were expressed by Dr. Muller in his presidential address.

"This year for the first time your Program Committee has been embarrassed by the quantity of material offered and found it difficult to follow the rule of accepting all offerings from members. It seems to me that in the future, committees will find it expedient to select those papers which offer new thoughts or are sufficiently controversial to excite discussion."

One paper deserves special attention. Not for the presentation itself, but because of the battle of semantics which it precipitated. I refer to the paper "Pneumonectomy for Sarcoma of the Lung in a Tuberculous Patient" by Dr. Howard Lilienthal.

It is safe to assume that Dr. Graham was elated about the patient back in St. Louis who had survived the removal of an entire lung. It is not surprising, therefore, for him to discuss Dr. Lilienthal's pneumonectomy case in a confident way and to describe his now convalescent patient and the details of the case in a scholarly manner. The trespass into the field of etymology, however, was most unfortunate.

A portion of Dr. Graham's discussion is as follows:

Dr. Evarts A. Graham (St. Louis).—I was much interested in this case of Dr. Lilienthal because he operated upon his case just a short time before I performed a complete

*By authority of Dr. Ethan Flagg Butler's "little black book." Dr. Duff Allen, the Secretary could not be present because Mrs. Allen was having a baby. Dr. Butler was drafted to serve as secretary.

pneumectomy. In my case, however, fortunately the result was successful. I do not call it pneumonectomy, as Dr. Lilienthal does, because I have the support of the Oxford dictionary and various other dictionaries to call it pneumectomy instead of pneumonectomy.

The Oxford dictionary and other references did not impress Dr. Pol. Coryllos who not only was a Greek, but knew the Greek language well.

Dr. Pol. N. Coryllos (New York).—(Illustrating on blackboard.) First a point of etymology. I agree with Dr. Lilienthal that the correct Greek term for excision of the lung is "pneumonectomy" and not "pneumectomy" as proposed by Dr. Graham. The lung in Greek is *πνεύμων-ονος*, whereas *πνεύμα-ατος* means air or spirit. The second part of the term, "*εχτομή*" (excision) indicates the action exerted upon the lung, therefore the latter must be placed in the genitive (*πνεύμονος*) the radical of which is *πνεύμων*—so that the composed word will be "pneumonectomy." "Pneumectomy" on the contrary means "resection of air," and if correctly constructed should be pneumatectomy. It is according to the same rules that are constructed the terms gastrectomy, ureterostomy, salpingectomy, otorhinolaryngology, etc. I hope that this literary digression will help to settle that question.

This must have been a bitter pill since Dr. Graham was a real stickler on diction, grammar, and particularly superior about his knowledge of word roots.

It is impossible to determine accurately the exact number of surgeons who were engaged in a significant amount of thoracic surgery twenty-five years ago. Certainly no more than a hundred in the United States and Canada, probably considerably less. Only a few limited their work to the chest and most of them were prominent general surgeons who were interested in developing a new field. There were a few physicians with little or no surgical training attempting to do chest wall operations on patients in the tuberculosis sanatoriums.

Opportunities for training in thoracic surgery were limited. In most instances the program was integrated with general surgery with sometimes the addition of fellows who might spend an extra year or two in clinical work and research projects connected with thoracic surgery. A few exceptions, however, were developing. In January of 1933, Dr. John Alexander established at the University of Michigan a training program in thoracic surgery with a minimum appointment of two years' duration. Others, including Dr. E. J. O'Brien, Dr. Pol. Coryllos, and Dr. Louis Davidson established residencies devoted exclusively to surgery of the chest.

Two philosophies were beginning to develop. One, a concept of exclusive specialization in thoracic surgery. The second and more popular then, additional training for the surgeon who might also operate in the chest, but remain principally in general surgery.

Twenty-five years ago only a small minority accepted the feasibility of specialization. The field seemed too small; the patients were poor physical and financial risks; and economic suicide was often predicted for those foolish enough to desert general surgery.

Reliable data concerning the number of surgeons in this country limiting their practice to thoracic surgery are not available. It has been estimated that in the neighborhood of two hundred and fifty do so. The remainder of those

now certified by the Board of Thoracic Surgery do not. After twenty-five years the differences of opinion concerning specialization remain, but in different proportions.

It is apparent, however, that the dire financial disasters predicted for the specialists were unwarranted. An important factor, of course, has been the thoracic surgeon's successful wrestling match with nose and throat specialists for the control of endoscopes.

Originally the members of our Association were not receptive to establishing a board of Thoracic Surgery. It was first discussed in 1936 and a committee appointed to study the question. In 1937 the committee's opinion was that there was no need for certification of thoracic surgeons by a separate Board at that time.

In 1945, a second committee was appointed and made its report in 1946. A recommendation was adopted favoring the formation of a Board of Thoracic Surgery as a subsidiary of the American Board of Surgery. A plan of organization was established in 1948 by the Eggers Committee. And the Board of Thoracic Surgery was incorporated under the laws of the State of Michigan on Aug. 31, 1950, as a subsidiary of the American Board of Surgery.

There are now two hundred and twenty-eight founder members, and in the decade of existence five hundred and thirty-four candidates have been certified by examination.

A total of seven hundred and sixty-two surgeons have a certificate stating they are properly qualified to operate upon the chest of their fellow man. The recent crop of thoracic surgeons has been abundant. Two hundred and fifty-nine have been certified in the past 3 years. It might appear that the principle of supply and demand is being violated.

The establishment of first the American Board of Surgery and later its subsidiary, the Board of Thoracic Surgery, stimulated surgical segregation. Influences on rank and assignment during World War II gave a final and mighty emphasis to Board certification.

Practically all surgical specialties were originally developed by general surgeons, but in most instances have become distinct and separate fields of endeavor as the specialty develops.

Incredibly complete severance with one of the oldest surgical specialties has been so radical that surgeons certified by other Boards must relinquish the previously conferred sheepskin to become eligible for certification.

Fortunately, there is little chance of surgical contamination in this particular specialty since only one year of internship is required before the special training.

The tendency to drift from old patterns of emphasis on general surgery is shown by the requirements of other Boards. For example, the Neurosurgical Board requires only one year of surgical internship preliminary to training in the specialty. The Board of Orthopedic Surgery specifies a year of internship and one year of general surgical residency as a preliminary.

The Board of Thoracic Surgery is a subsidiary of the American Board of Surgery. Total dependence on general surgery is established if one examines

the definition of subsidiary—meaning: furnishing aid, auxiliary, tributary, as a capacity; secondary.

No Board has more rigid requirements. Certification by the American Board of Surgery and an additional two years of training.

Our rigid standards resulted from the philosophy that all engaged in thoracic surgery must first be trained in general surgery. Certainly one of the reasons for this particular emphasis was to discourage physicians who entered the field via the chest wall route without previous experience in surgery. Time and the combination of antibiotics with the modern surgical treatment of tuberculosis have practically eliminated this group. Probably another factor was the failure of other specialty Boards to require adequate basic surgical training.

Fortunately the original plan of two written and two oral examinations has been condensed with the elimination of the written examination in thoracic surgery. The first part of the general surgical Board, however, now includes a certain prescribed percentage of questions relating to thoracic surgery. This change, however, has created problems for the young surgeon who has little or no contact with thoracic surgery during the general surgical training.

It is easy to comment that in a properly integrated service the trainee should have sufficient background to answer correctly the questions on thoracic surgery. In many instances, however, this is simply not the case. Depending upon the pattern of training the general major and the thoracic major might find this examination quite difficult.

There are now eighty-nine hospitals approved for training in thoracic surgery. One wonders if there are really eighty-nine institutions in existence in our country with sufficiently varied clinical material and available teachers. This is a particularly pertinent question in regard to surgery of the heart and great vessels.

Neither the American Board of Surgery nor the Board of Thoracic Surgery attempt to define independently an acceptable training program. Residencies in surgery are judged by a conference committee consisting of representatives of the Council of Medical Education of the American Medical Association, the American College of Surgeons, and the American Board of Surgery. Moreover, the American Board of Surgery and its subsidiary, the Thoracic Board have made it clear that they are not concerned with special privileges or recognition their diplomates may obtain by virtue of certification. This is in sharp contrast to many specialty groups who make their own ground rules for training programs and emoluments for their certificates.

Thoracic surgery is now a distinct specialty and it is safe to predict it will become even more so. And, it makes little difference how each of us in this Association feels about it. The public and the nonsurgical segment of the medical profession have nurtured specialists and, in fact, demand them.

Otherwise intelligent members of our profession are very apt to classify a colleague as a Board man or not a Board man. The layman has a similar

approach with different terminology. The surgeon is a heart man, lung man, or some kind of man whom they associate with the repair or eradication of various vital or semivital organs.

It would be difficult for surgeons who have fulfilled the qualifications for certification in thoracic surgery to lose interest in general surgery. Once, however, they are labeled they are often confined to a single field of endeavor. This is particularly true of those in private practice. A small minority of surgeons in full time clinics and medical schools are not quite so limited, but even in these institutions the trend is toward regional specialization as far as operating is concerned.

Although the battle for various organs continues, the chest man has been gaining ground, or perhaps better stated, not infrequently successfully raids outside of his designated body cavity.

On the left he can slip through the diaphragm for spleens or stomachs without treaty violation serious enough to cause a major battle. And on the other front, a thyroid gland which isn't well above the sternal notch is fair game.

Conversely, surgeons now designated as generalists are fighting valiantly on two fronts. They have been pushed down on the left flank by the chest specialist and forced upward on the other major battle-field by the colon-rectal specialist who also has been commissioned by his Board to engage in this war. The war with the neurosurgeons was lost years ago. For the most part bones have been taken away by the orthopedist, and even burns by the plastic surgeon. The general surgeon still controls the right flank of liver and gall bladder and the middleground, but his supply lines are thin.

This half facetious, but not far from the truth, description of the state of surgical affairs may create serious problems for the young surgeon.

In the five to seven years after graduation from medical school this now not so young surgeon, trained in general and thoracic surgery, leaves the institutional nest—not because he is incompetent or not wanted—the nest is full, and there is the possibility he has had about all of the nest he can tolerate. He searches and finds a community he admires and in which there is a reasonable chance to make a living. He may then find it is expedient or totally necessary to pattern his practice by default.

If in the community there are three well-established, fairly young thoracic surgeons and the majority of the general surgeons are senile or well on the way—general it will be, or the converse may be true. In either event there has been a waste of talent, energy, and money.

Prerequisite training in general surgery before specialization I sincerely hope will continue. And it is proper to suggest that other specialties would profit by following this example.

It appears, however, present standards or, better stated, rules for training are not realistic and perhaps untenable.

For example, is it really necessary in every case to spend four years following internship in general surgery before training in thoracic surgery? Is it reasonable to prescribe a six months' minimum credit for the study in basic

sciences? For the interested student the study of physiology, chemistry, or almost any science might result in a potential contributor to the progress of surgery. Conversely, it would be utterly ridiculous to require all, including the uninterested to follow the same pattern of postgraduate education.

These questions are easy to ask, but extremely difficult to answer in a specific way. It is suggested, however, there be fewer rules and that more attention be given to quality of training rather than quantity in terms of years.

A quarter of a century has passed since the pneumonectomy of our case report was performed by the man whose memory we honor today. During this time, thoracic surgery has progressed from a faltering, dangerous formative stage to a recognized surgical specialty.

More than any other organization in the world our Association will influence the trends of the next twenty-five years. It is appropriate then, to ask ourselves just what have we done and more important, what are we going to do.

Thanks are expressed to Remington Rand, Inc., St. Louis, for providing photostats of the original records which had been placed on microfilm.

I am deeply indebted to Doctors Ackerman, Bradley, Burford, and Moyer who made records and the photographs of the specimen available, and to Dr. James Gilmore who gave permission to review the case report.