

The Journal of THORACIC AND
CARDIOVASCULAR SURGERY

Presidential address

Twenty-five years' experience with the surgery of patent ductus arteriosus

John C. Jones, M.D., Los Angeles, Calif.

It is the prerogative of the president of a surgical society to discuss any subject that he wishes, and very often he chooses some philosophic aspect of surgery or medicine that has long been his secret, favorite, thought-provoking hobby. Philosophy and philosophic discussion have not been my forte, so I have chosen to talk about my 25 years' experience with the surgical treatment of patent ductus arteriosus. I have chosen it because I believe it is important that every young surgeon should know each and every detail of the techniques, pitfalls, and complications of ductus surgery before he operates upon his first patient. This he can accomplish only by studying the recorded experiences of his predecessors so that he may profit by their contributions, heartaches, and mistakes, inadvertent to be sure, but nevertheless of paramount importance to both patient and surgeon. I was furthermore stimulated to this subject because I heard

of a death from hemorrhage on the operating table when a young, inexperienced resident performed his first ductus operation in a large hospital where clinical material is plentiful and ductus surgery is beneath the dignity of the upper echelon of staff.

Historically, Monroe of Boston in 1907 described a method for the ligation of patent ductus arteriosus which in 1888 he had demonstrated to be feasible on infant cadavers. In 1900, Gibson, in Edinburgh, for the first time reported the classical clinical findings of a patent ductus arteriosus, but it was not until 1937 that John Strieder, of this Association, first attempted ligation of the ductus in a patient with fulminating subacute bacterial endocarditis. Along with Graybill and Boyer, he reported the ductus closure was incomplete after the patient died on the fourth postoperative day of gastric distention and aspiration. Shortly thereafter, Robert Gross, immediate past president of this Association, in August, 1938, successfully ligated the patent ductus of a 7-year-old girl, and 6 years later Gross reported the

first successful division and suture of a ductus. It is of interest that the history of the surgical treatment of patent ductus arteriosus centers entirely within Boston. However, one of the great contributions to this field was made by our good friend and member of this Association, Dr. Willis Potts, whose serrated ductus clamp made the division of the ductus a safe surgical procedure. In retrospect, thus began in a modest fashion the present era of this rapidly expanding field of cardiovascular surgery.

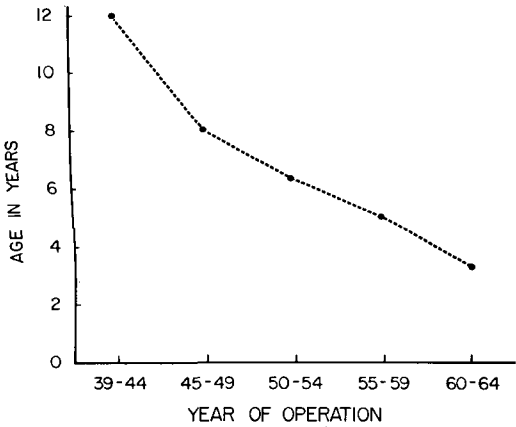


Fig. 1. Mean age of the patients at the time of operation, charted in 5 year periods.

Table I. Total series 1939-1964

266 Males
633 Females
899 Total number of patients
909 Total number of operations

Statistical data

We have carried out 909 operations on the patent ductus arteriosus on 899 patients (Table I). Actually, there were twenty-odd additional patients whose records of years ago were either lost or inadequate for statistical purposes and these are not included for obvious reasons. Females comprised 70 per cent and males 30 per cent of this group. Fifteen of the patients had visual disturbances, 13 of whom had cataracts and 2 were blind. Eighteen of the patients were mentally retarded. Their ages varied from 10 days to 60 years (Fig. 1); both extremes had successful operations in spite of their heart failure just prior to surgery. The mean age of the patients at the time of their operations, charted in 5 year periods since 1939, has progressively receded from 12 years to 3.5 years, denoting the trend of earlier

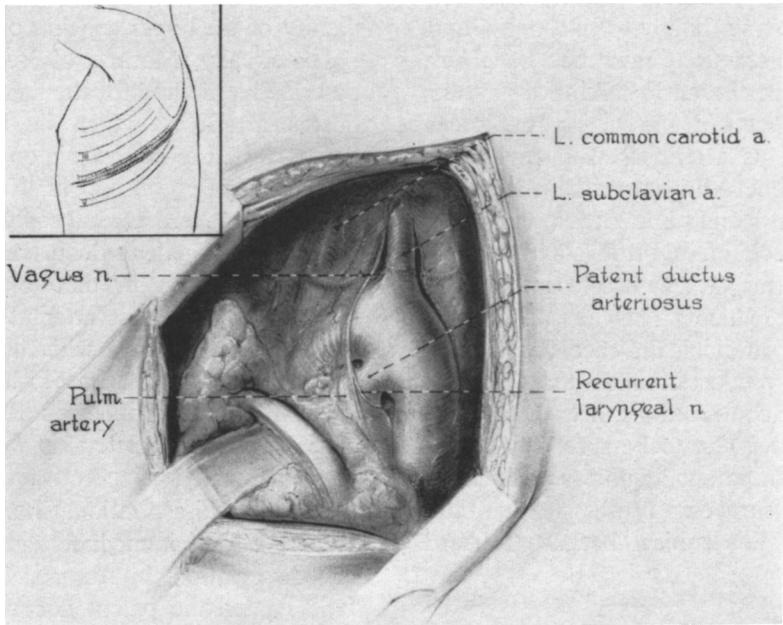


Fig. 2. Anatomy and technique of the patent ductus arteriosus from the posterolateral approach.

surgical treatment for this lesion. There were 3 adults, one aged 60 years, operated upon in the past 5 years, and were these excluded, the mean age of the patients would have been appreciably lower.

Technique

The posterolateral exposure is used in all cases, the fourth rib being resected and the

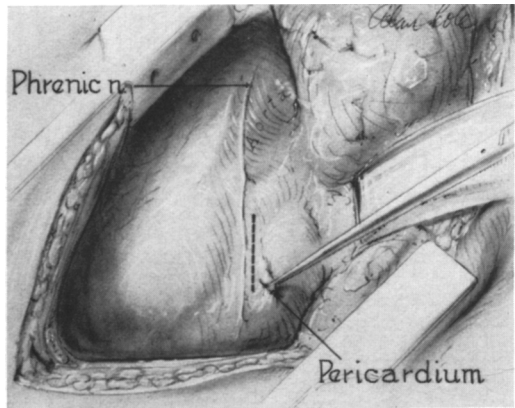


Fig. 3. Incision in the pericardium just lateral to phrenic nerve and over the left atrium and pulmonary artery.

rib spreaders placed (Fig. 2). The posterolateral exposure has many advantages. First of all, by mobilizing the aorta above and below the ductus, it is possible to obtain the best exposure and dissection of the ductus, both anteriorly and posteriorly under direct vision. There is less chance of recurrent laryngeal nerve injury, for the nerve is identified both in front of and behind the aorta. We usually open the pericardium (Fig. 3) over the pulmonary artery just behind the phrenic nerve and allow the pericardial fluid to escape, particularly in young infants where the large heart and the pericardial fluid may impede lung retraction and adequate exposure to the ductus. The fibrous pericardial reflection (Fig. 4) is cut posterior to the ductus in order to obtain a full length of ductus to divide. In about 15 per cent of the cases there is one or more mediastinal branches of the aorta posteriorly at the level of the ductus that may be torn if not identified or divided before the ductus dissection. These are not usually seen with the antero-lateral approach and their bleeding is difficult to control if they are injured during

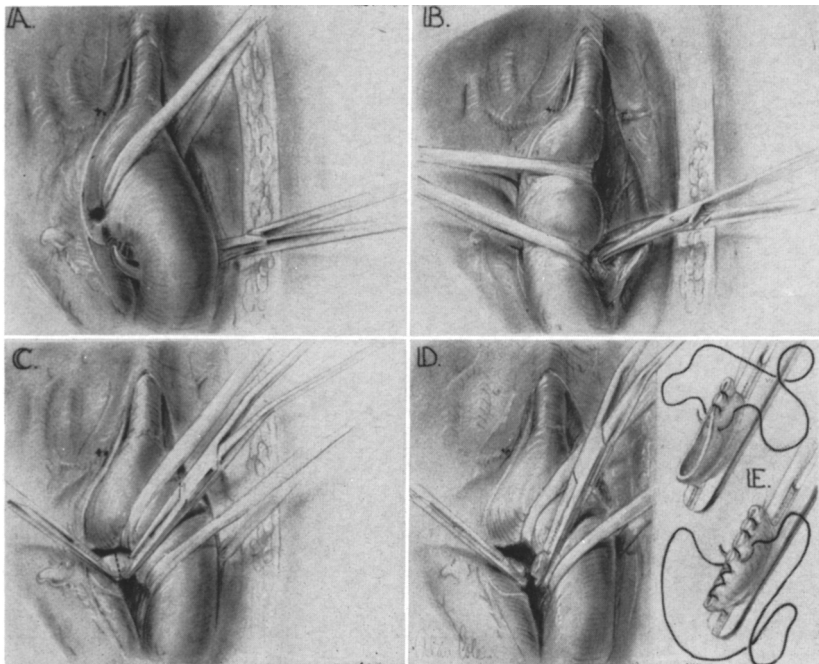


Fig. 4. The dissection and mobilization of the aorta with division of the ductus and closure of the stumps.

the ductus dissection. Should inadvertent hemorrhage occur during the dissection and division of the ductus, immediate control of the bleeding is facilitated by easy access to the pulmonary artery through the slit in the pericardium anteriorly, and to the aorta posteriorly with this technique. Since the

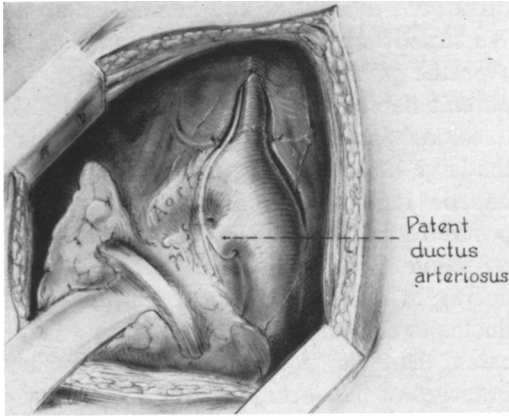


Fig. 5. The anatomy of the very short patent ductus arteriosus from posterolateral approach.

aorta and pulmonary artery are under constant control, the bleeding area is readily exposed and easily repaired by suture. Finally, it is seen that, with tapes passed around the aorta above and below the ductus, the maximum length of the ductus is available for division of this structure. The ends of the ductus are closed with double continuous suture of silk.

In the event that the patent ductus is short and wide (Fig. 5), the technique that is followed is one that was suggested by Dr. Clarence Crafoord, who accidentally discovered it for the first time while controlling a bleeding tear in the ductus. The ductus is exposed (Fig. 6) and tapes are passed around the aorta, both above and below the ductus, and the short ductus dissected as already described. We use the three-clamp method as is seen in Fig. 6. First of all, the superior aortic clamp is placed, the ductus is then clamped flush with the pulmonary artery, and then a third clamp is placed

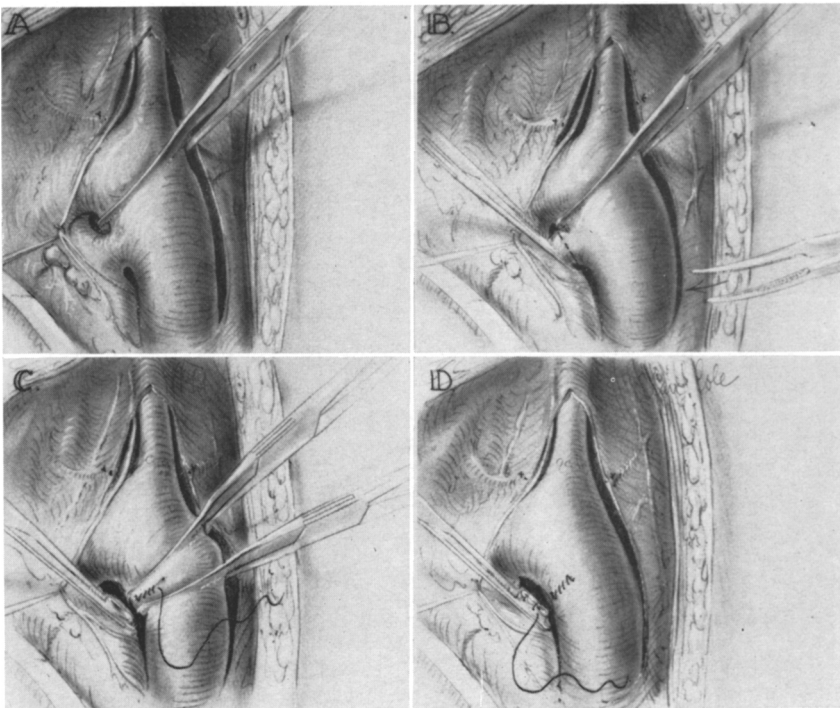


Fig. 6. The aorta has been mobilized and the ductus dissected, clamps placed on aorta above the ductus, on the pulmonary end of the ductus, and finally on the aorta below the ductus. Ductus divided flush with the wall of the aorta and the aorta closed transversely.

across the aorta below the ductus. The ductus is divided by knife at the wall of the aorta in order to leave adequate cuff of ductus to suture on the pulmonary side of the ductus. The aorta is then sutured promptly before the ductus is sutured and this is accomplished by transverse suture after bringing the aorta clamps closely together. The aortic clamps are released as soon as possible so that not too long a period

of time (less than 10 minutes) is taken with the clamping and suturing of the aorta. Finally, the pulmonary artery side of the ductus is sutured leisurely. Seen above the aortic clamp is a ridge at the junction of the aorta with the subclavian artery, where the leakage of chyle is apt to occur in the event that there is a radicle of the thoracic duct crossing at this area.

The technique of dividing the ductus with resection of coarctation of the aorta is much the same as just described. After the aorta is mobilized (Figs. 7 and 8), the ductus is dissected with traction tapes passed around the aorta above and below the coarctation. The aorta is clamped above and below the coarctation and, after the pulmonary end of the ductus has been clamped, the ductus is divided and sutured. Then the coarctation is resected along with stump of ductus and the end-to-end anastomosis is carried out. Interestingly enough, in all of the children upon whom we have operated, we have only been forced to implant grafts in 3 patients; it is our belief that in children quite long distances of the aorta are resectable and still

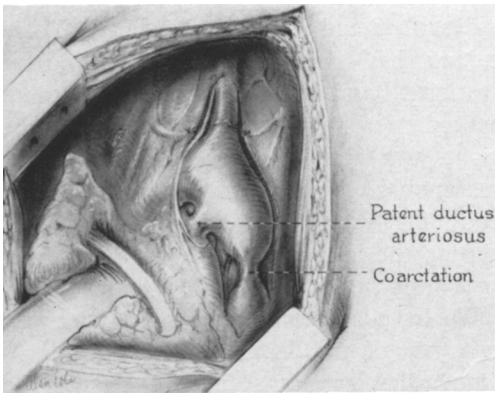


Fig. 7. The anatomy of the patent ductus arteriosus with coarctation.

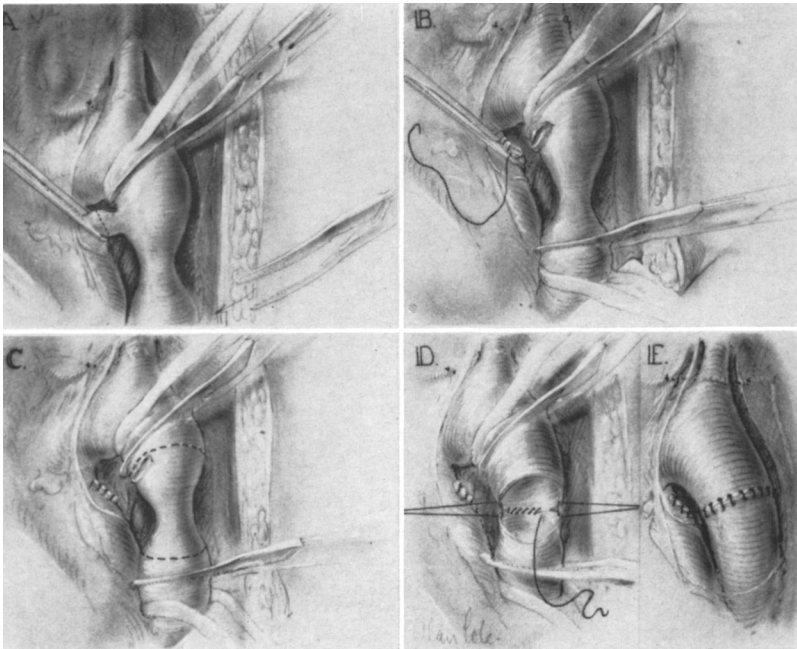


Fig. 8. Aorta and ductus dissected and clamps placed upon the aorta above and below the coarctation and upon the ductus close to the pulmonary artery. Division and suture of patent ductus and resection of coarctation with end-to-end anastomosis.

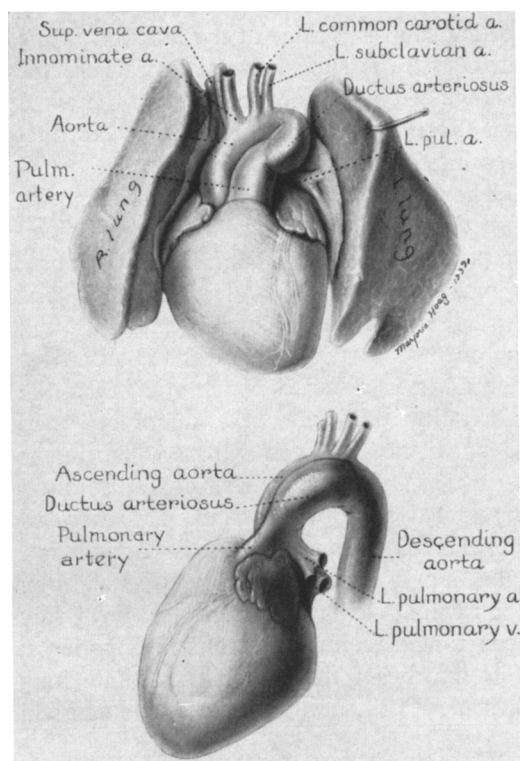


Fig. 9. Artist's drawing of an autopsy specimen shows aneurysm of the patent ductus arteriosus in the very young infant.

an end-to-end anastomosis accomplished. In adolescents and adults, appropriate grafts are implanted, as the need arises, by means of this same technique.

In 1939, we saw a young infant who died of a large aneurysm of the duct, and the artist's drawing of this autopsy specimen is shown (Fig. 9). It is seen that the aneurysmal dilatation of the ductus is in fact larger than the arch of the aorta; we have encountered two of these aneurysms of the duct in young infants. The technique here is as described and illustrated in Fig. 10. These patients had uncomplicated patent ductus arteriosus and the division and suture method was feasible without event. The ductus was easily dissected after the aorta was mobilized with traction tapes, as already illustrated. The suture line is here seen as the long suture line on the pulmonary artery.

We have operated upon two adults with aneurysm of the ductus arteriosus and, although the surgery seemed at first to be formidable, following this technique (as in Fig. 11) the aneurysms were resectable and divisible without difficulty. After mobilization of the aorta, the pulmonary artery was dissected and, finally, the aneurysm itself was dissected and could be resected after

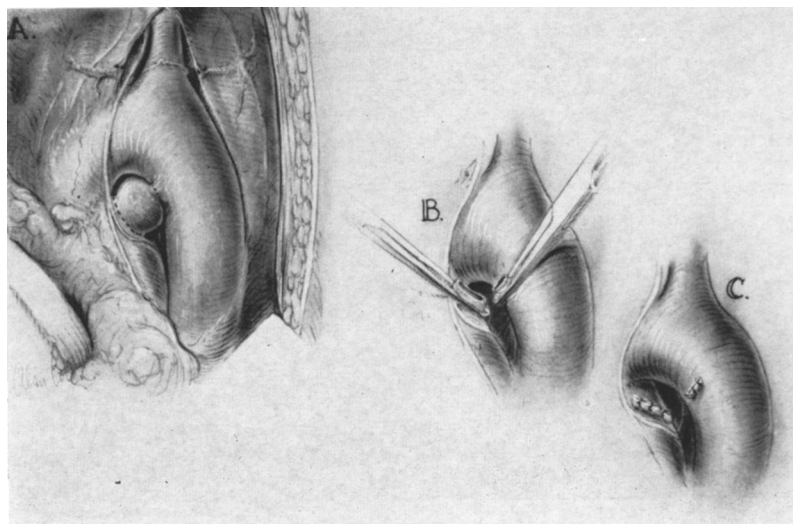


Fig. 10. Aneurysm of the patent ductus arteriosus in an infant. Surgical technique of division of the ductus.

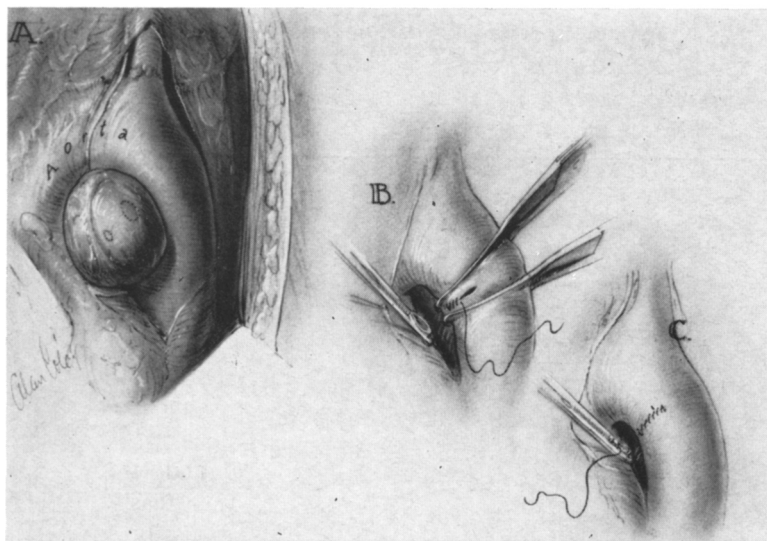


Fig. 11. Drawing of aneurysm of the patent ductus arteriosus in an adult shows technique of resection of aneurysm and suture of the aorta and of the ductus stump.

clamps had been placed on the aorta above and below the aneurysm and on the pulmonary artery, medial to the aneurysm. There is seen the method of transverse closure of the aorta when the clamps are brought close together so that there is no impingement on the lumen of the aorta. The wall of the aorta is closed first and aorta clamps are removed before the pulmonary artery end of the ductus is sutured.

I have had no experience with the extrapleural approach to the patent ductus which has been advocated more recently; therefore, perhaps, I should not criticize its use. I see no valid advantages to favor it, but experience has led me to believe that the extrapleural approach has definite disadvantages, for I am an advocate of a wide open exposure that may afford access to all of the structures within the hemithorax that I am exploring.

We have encountered over the years but one right-sided patent ductus arteriosus (Fig. 12) which was ligated on June 22, 1945, through a right posterolateral thoracotomy. The artist's drawing depicts a right-sided aortic arch and a short ductus behind the superior vena cava. It was completely ligated and the ductus murmur disappeared. However, subsequently this patient still had

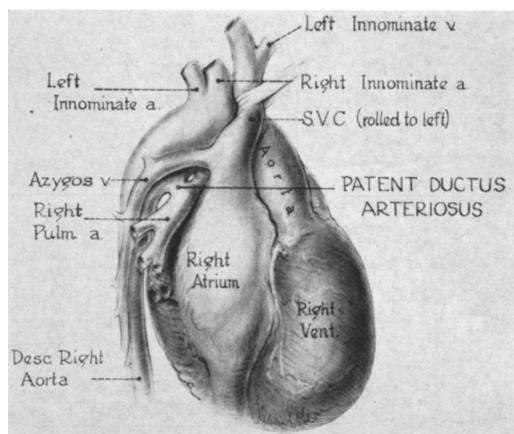


Fig. 12. An artist's drawing depicts a right-sided patent ductus arteriosus as seen through a right posterolateral approach.

a precordial systolic murmur which, on catheterization, proved to be due to a residual atrial defect (Fig. 13). The catheterization data showed that the ductus itself had been obliterated and that there was residual flow through the atrial defect of 6.3 L. per minute. Subsequently, this patient was seen in several different clinics and was observed to be doing well, but her parents refused further surgery and when last heard from she still had an atrial defect.

CARDIOVASCULAR RESEARCH DEPARTMENT
CHILDRENS HOSPITAL — LOS ANGELES
CARDIAC CATHETERIZATION DATA

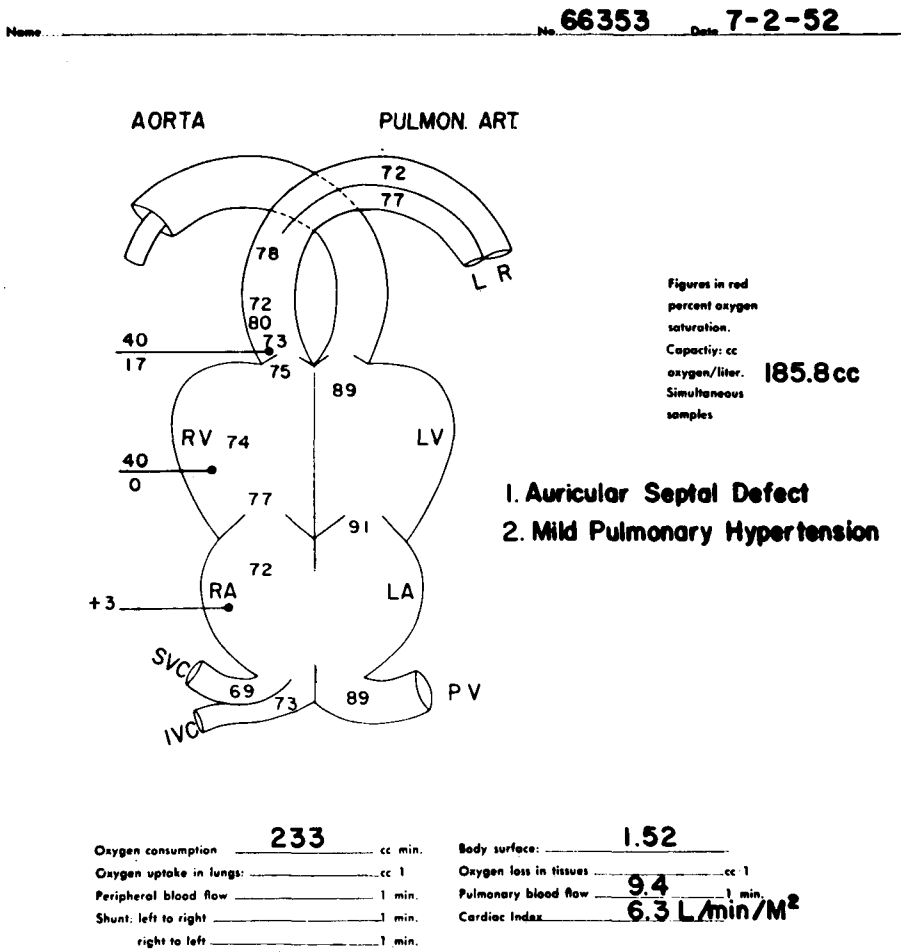


Fig. 13. Catheterization findings in the patient after ligation of the right-sided patent ductus arteriosus shows residual atrial septal defect.

Other lesions

In this case series, the patent ductus arteriosus was complicated by other cardiovascular or visceral lesions preoperatively in 126 patients (Table II), an incidence of 15 per cent. Coarctation in 38 and ventricular septal defect in 31 patients comprised 57 per cent of the lesions accompanying the patent ductus. Pulmonary stenosis, anomalous right subclavian artery, atrial septal defect, and aneurysm of the pulmonary artery or the ductus occurred less frequently. There were 10 patients who came

with a ductus already complicated by sub-acute bacterial endocarditis, and there were, in all, seventeen miscellaneous lesions, such as congenital and acquired aortic stenosis, mitral stenosis, double aortic arch, congenital absence of left upper lobe, and anomalous pulmonary venous drainage. All thirty-eight coarctations were resected at the time of the division of the ductus and an end-to-end anastomosis of aorta was established. A large percentage of the pulmonary stenoses, ventricular and atrial septal defects have been repaired subsequently; four of

Table II. 126 Patients with ductus accompanied by other lesions (preop.)

Coarctation	38
Ventricular septal defect	31
Pulmonary stenosis	9
Anomalous subclavian artery	8
Atrial septal defect	7
Aneurysm of pulmonary artery or ductus	6
Subacute bacterial endocarditis	10
Miscellaneous	17

the anomalous right subclavian arteries were divided, the other four were considered to be innocuous and not in need of division at the time of the ductus surgery. Aneurysmal dilatation of the pulmonary artery and/or the ductus has been dealt with successfully at the initial operation in all 6 patients and is discussed under the description of operative technique.

There were 10 patients who had preoperative subacute bacterial endocarditis, 3 of whom had preoperative antibiotic therapy, and their subsequent surgery was uneventful. Three patients had unsuspected subacute bacterial endocarditis prior to operation which was proved subsequently. One 14-year-old boy had had a rupture of the ductus at the time of its clamping that resulted in considerable blood loss and ne-

cessitated the clamping of aorta more than 25 minutes. Biopsy of the friable ductus confirmed for the first time the presence of subacute bacterial endocarditis. The difficult repair of friable aorta and delay in removal of aorta clamps caused a paraplegia in a patient with an otherwise uncomplicated convalescence. This patient has done very well for many years since the operation. The second, a 13-year-old boy, had a tear of the friable ductus during operation, and, at the time of division, a biopsy was taken. The hemorrhage was controllable and his convalescence was uneventful. The biopsy of the torn ductus revealed an active endocarditis with vegetations demonstrable on microscopic examination. The third patient with unsuspected preoperative subacute bacterial endocarditis in whom the ductus was injured had copious hemorrhage controlled, but, at the conclusion of the division and suture of the ductus, cardiac arrest ensued and the patient was not resuscitated. Autopsy revealed sclerosis of the ductus and active bacterial endocarditis and active rheumatic heart disease. All 3 of the latter patients were not suspected of having subacute bacterial endocarditis before their operation, but careful review of their histories indicated frequent respiratory tract infections. Four other patients early in the series,

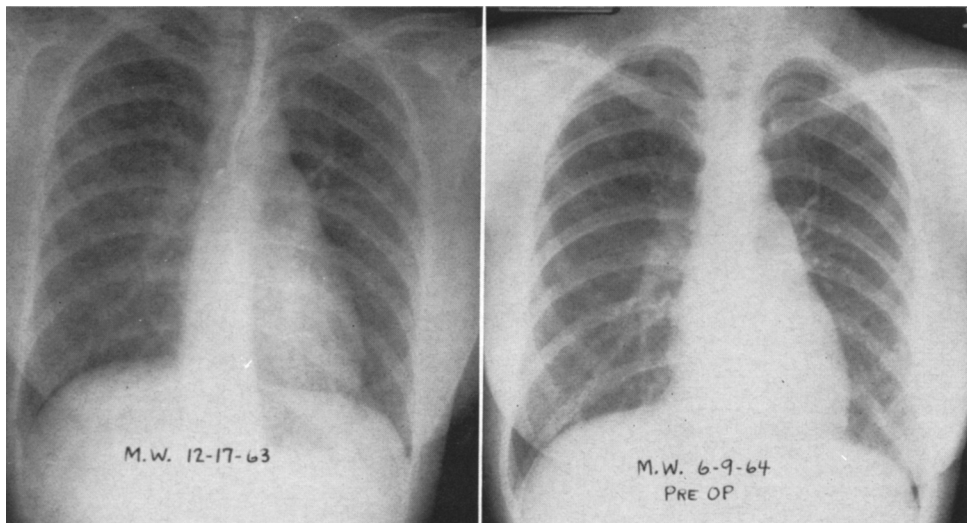


Fig. 14. Chest roentgenograms of patient before division of patent ductus arteriosus reveal only a prominent pulmonary artery.

who had preoperative subacute bacterial endocarditis, were operated upon without treatment and all died of their infection postoperatively. One of these patients had a ligation, the others a division of the ductus. There were five deaths and five cures

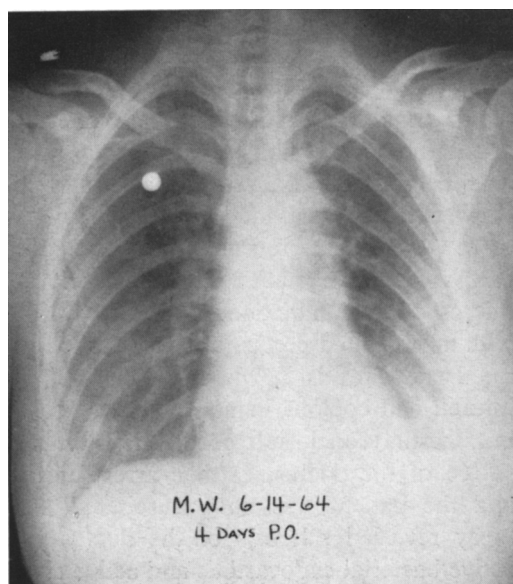


Fig. 15. Chest roentgenogram of patient made 4 days after division of patent ductus arteriosus reveals mild pleural opacity and minimum widening of the mediastinal shadow on the left.

in the group of 10 patients with preoperative subacute bacterial endocarditis and all of the cures were in those who had had division of the ductus. It can be safely assumed that subacute bacterial endocarditis discovered at or after operation occurs in patients who had unsuspected subacute bacterial endocarditis *before* surgery in the vast majority of instances.

I should like to review briefly the course of events of a recent operation in a classical case of subacute bacterial endocarditis, but is not included in this statistical study because we did not operate upon the patient initially.

A 20-year-old woman with mycotic aneurysm of the aorta was referred to our care several weeks after division and suture of a patent ductus arteriosus. She had been well except for recurring streptococcal pharyngitis (beta hemolytic type A) at 2 months and 1 month preoperatively which had necessitated postponement of surgery. Following oral and parenteral penicillin, the follow-up throat culture was negative 10 days before operation. Roentgenograms of the chest (Fig. 14) made before surgery had not changed and showed only a prominent pulmonary artery. The division and suture

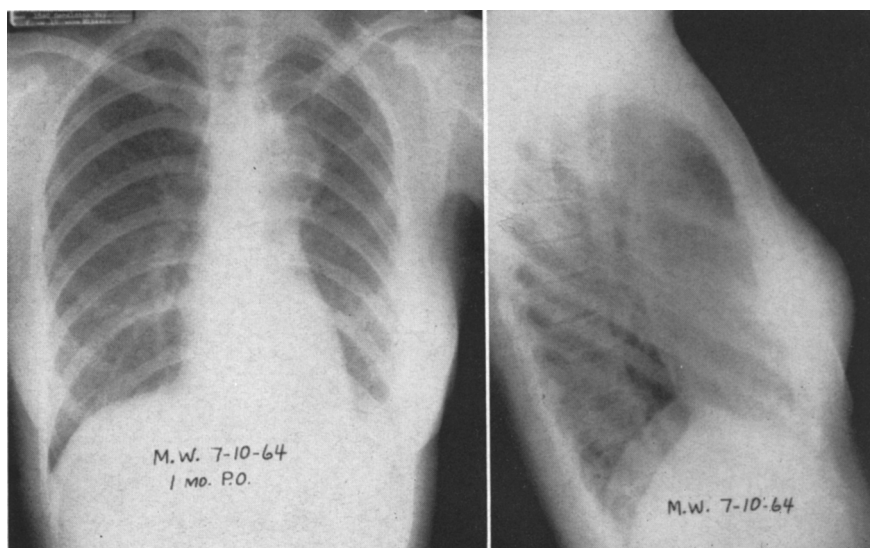


Fig. 16. Chest roentgenogram of patient made 1 month following division of patent ductus arteriosus shows an aneurysmal dilatation of the aorta without cardiac enlargement.

of patent ductus arteriosus (June 10, 1964) had been without event and the convalescence was uncomplicated, so that she was discharged on the ninth postoperative day. Roentgenograms made on June 14, 1964,

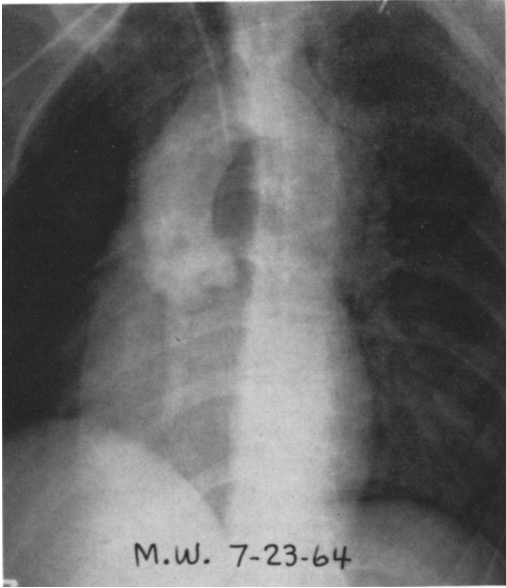


Fig. 17. Aortogram of same patient made 6 weeks following division of ductus reveals an aneurysm of the descending aorta from the left subclavian artery downward for a distance of approximately 4 to 5 inches.

showed a slight residual opacity (Fig. 15) and minimum widening of the mediastinum in the left hilar area. On July 6, 1964, 4 weeks after operation, she became ill and complained of generalized aching, vomiting, fever as high as 102° F., retrosternal pain, and hoarseness. She was again treated with oral penicillin by her own physician for 2 days and partial improvement occurred. She was then seen by her cardiologist on July 10, 1964, and was found to have, on roentgenogram, a bulging in the region of the division of the patent ductus arteriosus (Fig. 16). It was evident that infection had occurred in the area of the operation and that a mycotic aneurysm was present. She was hospitalized on July 10, 1964, and was treated with intravenous methicillin, 1 Gm. every 4 hours, and streptomycin, 1 Gm. every 12 hours. Blood cultures taken before this therapy were negative. Serial chest x-ray films revealed significant but only partial resolution of the inflammatory mass. A retrograde brachial aortogram was performed on July 23, 1964 (Fig. 17), which revealed that the dye passed into the aorta and into a large aneurysmal dilatation of the descending aorta, immediately below the left subclavian artery. When first seen by us

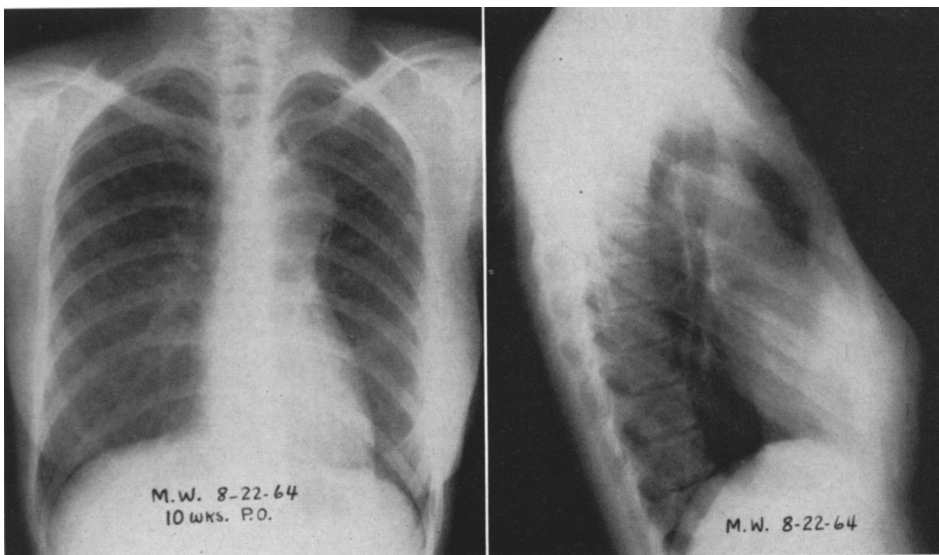


Fig. 18. Roentgenograms of chest of patient made 10 weeks after division of ductus and just before resection of a mycotic aneurysm of the aorta.

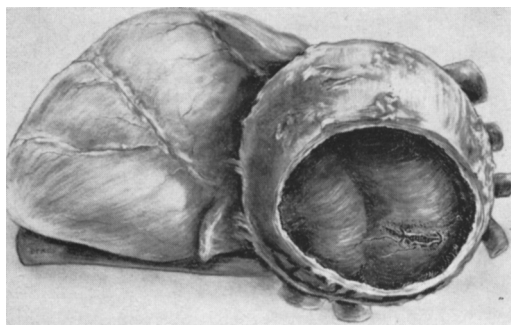


Fig. 19. Artist's drawing of mycotic aneurysm in situ shows the aneurysm to be opening into the aorta at the site of the suture line of the division of the ductus.

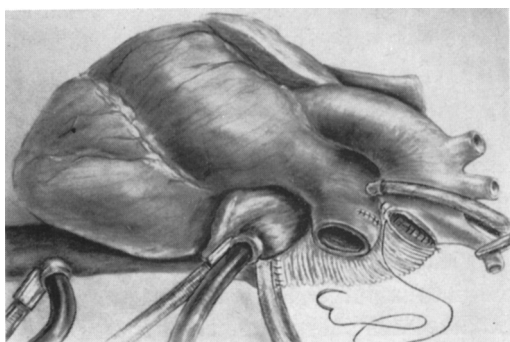


Fig. 20. Artist's drawing of the surgical replacement of the mycotic aneurysm and portion of aorta under left heart bypass.

on Aug. 22, 1964, roentgenograms (Fig. 18) revealed the presence of mycotic aneurysm 10 weeks postoperatively and the patient again had fever, malaise, hoarseness, marked pallor, and anemia, and it was obvious that resection of the aneurysm was imperative. She was hospitalized and massive intravenous continuous chemotherapy was given for a period of 6 days and then the aneurysm was resected, utilizing the left heart bypass. Fortunately, the pulmonary artery was not involved in, but was only adherent to, the aneurysm (Fig. 19). The opening of the aneurysm was at the site of the suture of the aorta alone and when clamps could be placed upon the aorta, both above and below the aneurysm, the latter could be resected with 4 inches of the aorta (Fig. 20). The fact that the pulmonary artery was not involved facilitated the resection, and a woven Teflon graft was implanted forthwith without difficulty. Unfortunately, a portion of vagus nerve had to be sacrificed with the inflammatory mass.

The patient had an uneventful immediate convalescence, was continued on intravenous chemotherapy, and had an entirely smooth postoperative course in the hospital. She had no residual cardiac murmur, hoarseness persisted, and the fluoroscopy of the chest was normal except for a slight fullness

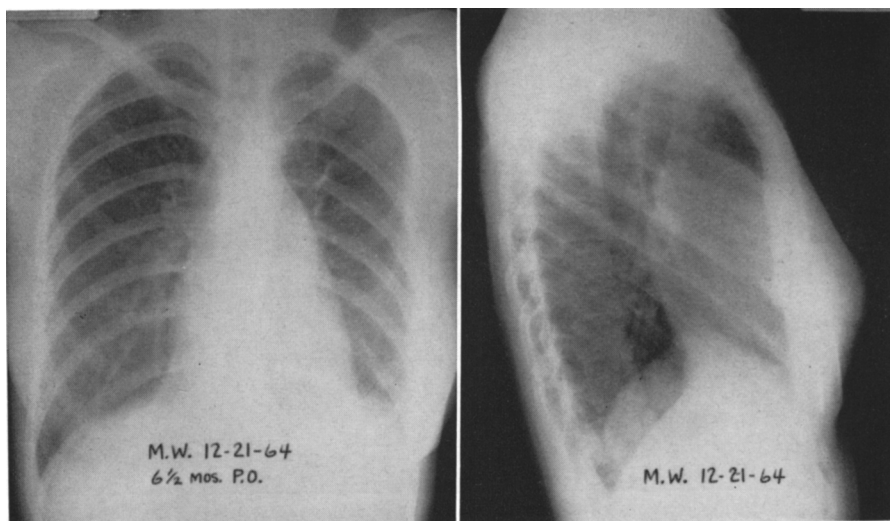


Fig. 21. Chest roentgenograms of same patient made several months after operation reveal only a prominent pulmonary artery and slight thickening of the pleura.

over the pulmonary artery when she was discharged from the hospital on Sept. 4, 1964. She was continued on 2 Gm. of oral Prostaphlin daily for 4 months following surgery. Culture from the aneurysm did not reveal any growth and several blood cultures on admission to the hospital, previous to her second operation, were likewise all negative. She is still well 7 months after operation, and the last roentgenogram (Fig. 21) revealed only slight prominence of the mediastinum directly over the pulmonary artery.

I believe that patients with ductus who have had recent infection should be well and free of antibiotic therapy for at least 3 or 4 weeks before surgical treatment and should have negative throat cultures 48 hours before their operation. I am most fearful of the patient who has been on long-term, so-called "prophylactic antibiotic treatment" for constantly recurring respiratory, nasopharyngeal, or other infection. If the patient cannot be free of infection without the antibiotic therapy, he should be treated as a potential candidate for subacute bacterial endocarditis and given massive continuous intravenous antibiotic therapy for 4 or 5 days before ductus or coarctation operation in spite of negative blood and throat cultures, normal sedimentation rate, etc. Patients with severe acne and infected skin areas should be treated in similar fashion, for the toll of postoperative subacute bacterial endocarditis is indeed a severe one and yet is entirely avoidable. Furthermore, the ordinary postoperative administration of antibiotics to the patient without complications should be discontinued on the third or

fourth postoperative day for obvious reasons.

The infantile ductus

It is estimated that patent ductus arteriosus comprises approximately 17 per cent of all congenital heart disease. In infancy, 15 per cent of these patients develop symptoms of failure to thrive, dyspnea, respiratory tract infection, and, of these, 15 per cent develop congestive heart failure which necessitates surgery at a very early age. The classical findings and the cardiac murmur are usually not present, but retrograde brachial aortography demonstrates the presence of ductus in a very high percentage of these extremely ill infants.

We have operated upon only the infants with overt heart failure who did not respond promptly to digitalization, and this conservative philosophy accounts for the relatively small number of operations upon infants under 1 year of age in this series of cases.

There have been 59 infants under 1 year of age operated upon for a patent ductus arteriosus (Table III). There were nine deaths (15 per cent mortality) and all of these infants had associated complicating congenital lesions seen at autopsy. Six of the deaths were due to heart failure, the others to respiratory tract infection, cachexia, and growth failure.

I am now of the opinion that all infants with a ductus and a history of heart failure should be operated upon, regardless of their response to digitalis and whether or not they have another complicating cardiac anomaly. If, after the ductus is divided,

Table III. 59 Patients under one year of age: 9 deaths (15 per cent)

No.	Age	Associated lesions	Cause of death
1	1 mo.	Multiple genitourinary, endocrine, and somatic anomalies	Cachexia
2	1 mo.	Ventricular septal defect, atrial septal defect	Growth failure
3	8 mo.	Mandibulofacial dysostosis, growth failure, coarctation	Heart failure
4	3½ wk.	Pulmonary stenosis	Growth failure
5	8 mo.	Ventricular septal defect	Heart failure
6	2 mo.	Pulmonary valvular atresia, coarctation	Tracheobronchitis
7	5 wk.	Ventricular septal defect	Heart failure
8	1 mo.	Coarctation	Heart failure
9	2 wk.	Coarctation	Cardiac arrest
			Heart failure

there is obvious pulmonary hypertension, then banding of the pulmonary artery is indicated at once. With this change in philosophy, I anticipate that more and more infants under the age of 1 year will have the ductus divided in our clinic with a substantial lowering of the mortality.

Pulmonary hypertension

Pulmonary hypertension in the presence of a ductus with or without other cardiovascular lesion, but with demonstrable right-to-left shunt, has been a most difficult surgical problem. We have operated upon 25 such patients and have had nine deaths, three of which occurred during the operation (Table IV). It is of interest that 5 patients who died had associated cardiovascular lesions and only one death was in an infant 5 weeks old. The other eight deaths were in patients 9 to 29 years of age.

The postoperative deaths all occurred within 4 hours to 3 days after operation, with one exception. The one late postoperative death occurred 4 years after surgery in a 13-year-old girl, while she was attending church. Deaths have been attributed to heart failure in spite of expert care by a cardiologist and all known medication and hypothermal adjuvant therapy. I believe that I have seen a number of patients with patent ductus arteriosus who have developed pulmonary hypertension before the age of 6 years, while under the observation of the

cardiologist—a convincing point in favor of operating upon the patient at an age earlier than 6 years or thereafter.

Ductus ligation

In our early experiences with the tape ligation of a patent ductus, we were cognizant of the hazards of ligating a large vessel such as the ductus, and have, in the past, reported our complications and long ago emphasized the work of Ballance, Halsted, and Reid on the ligation of large vessels in continuity. In the 61 ligations of the ductus, we had 12 patients in whom there was either recanalization or incomplete occlusion of the ligated ductus (Table V). Ten patients underwent a second operation and 8 of these are living and well, having had division and suture of the ductus, whereas 2 patients died as a result of the operation. Of the 2 patients that were not operated upon a second time, 1 is living, having declined surgery many years ago. The other late death was in a patient who had developed an aneurysm at the site of the ligation and, in addition, an aortico-bronchial fistula which seemed to have sealed off, leaving her without symptoms for the most part except for occasional small hemoptyses. She was well when her case was reported in 1949, and remained so until a sudden fatal hemorrhage occurred over 10 years after the ductus ligation when she was 46 years of age. In retrospect, this patient should have been operated upon as soon as she began raising blood, for a similar complication in a child in 1944 was cured by surgical treatment and she now has children.

Among the recanalized ligations (Table VI) there were two noninfected aneurysms of the ductus and side of the pulmonary artery. Both patients were operated upon and cured without complication.

There were two deaths as the result of reoperation upon an already ligated ductus. One of these patients died of infection of lung and the pleura, subacute bacterial endocarditis, and a mycotic aneurysm at the site of the ligation. The other died at operation as the result of hemorrhage at the site

Table IV. 25 Patients with preoperative pulmonary hypertension: 9 deaths (36 per cent)

No.	Age (yr.)	Associated lesions	Predominant shunt	Time of death after surgery
1	9		R → L	Operative
2	11	Coarctation	R → L	4 hr.
3	19		R → L	1st day
4	22		R → L	Operative
5	13	Coarctation	R → L	4 yr.
6	5 wk.	Coarctation	R → L	Operative
7	18	Coarctation	R → L	2 hr.
8	14	Ventricular septal defect	R → L	3rd day
9	16		R → L	2nd day

Table V. 61 Ductus ligations: 12 recanalized

Fate of patients in whom there was recanalization	
10 Reoperated	
8 Living after 2nd operation	
2 Died after 2nd operation	
2 Not reoperated	
1 Died of ruptured ductus aneurysm	
1 Living, declined reoperation	

Table VI. Late complications of ductus ligation, (61 ligations: 12 recanalized)

2 Aneurysm reoperations—successful
2 Aorticobronchial fistulas
1 Repaired—well
1 Died, hemorrhage (no reoperation)
2 Patients who had reoperation died
1 Subacute bacterial endocarditis post-operatively
1 Operative hemorrhage

Table VII. Major operative complications (11—91 per cent deaths)

		Died	Living
Cardiac arrest			
Ligation	0	—	—
Division	6	6	—
Hemorrhage			
Ligation	1	1	—
Division	4	3	1

of the ductus ligation and adjacent aorta and pulmonary artery.

Major operative complications

There are two major operative complications associated with the surgery of patent ductus arteriosus (Table VII), namely cardiac arrest and major bleeding, and only 1 in 11 patients survived in this series. Six patients had cardiac arrest during or just after operation, and all died. Three of them had pulmonary hypertension, 1 had endocardial fibrosis; there was one anesthetic death, and one of unknown etiology included in this group.

There were three fatal hemorrhages in 4 patients, and these deaths were due to major blood loss as the result of injury or tear of the ductus and/or aorta. The one

survivor had acute vegetations in the torn ductus. With our present technique, we have not had a death from hemorrhage since 1955, and that was in a 22-year-old patient who had pulmonary hypertension. The second death was in 1954 in a reoperation of a previously ligated ductus. The remaining death was in 1946, due to hemorrhage from a tear of a friable duct in a 6-year-old child.

Postoperative complications

The commonest complication following thoracotomy for ductus surgery was pulmonary atelectasis (Table VIII). Before the availability of antibiotics and intermittent positive pressure breathing, persistent pulmonary atelectasis occurred in 18 patients, but since this combined therapy we have not seen it. Eventually, all patients responded to bronchoscopy, bronchodilator, and expectorant agents and humidified atmosphere.

Pleural effusion requiring single or multiple aspiration occurred in 13 patients, none of whom had had postoperative pleural drainage by tube. Since we have used drainage after almost all thoracotomies, we have not seen this complication. However, before the advent of efficient chemotherapeutic agents, we were reluctant to close drain the chest except in unusually wet pleural cavities as the result of the extensive cutting of adhesions.

Hemothorax likewise has not been a complication since the routine drainage of the pleural space, and we have not operated a

Table VIII. Postoperative complications (10.5 per cent)

Atelectasis	18
Pleural effusion	13
Recanalization	12
Hemothorax	7
Recurrent nerve injury	7
Pneumothorax	6
Tracheobronchitis	6
Chylothorax	5
Subacute bacterial endocarditis	4
Paraplegia	1
Infections and miscellaneous	17
	96

second time for intrapleural or mediastinal hemorrhage. Multiple aspiration fortunately cared for the complication which probably would not have occurred if tube drainage with prompt lung expansion had been instituted at the close of the operation.

Recurrent laryngeal nerve injury has occurred in 7 patients, but in only 2 has there been permanent paralysis. The paresis cleared in the 5 remaining patients, probably indicating trauma or edema as the cause of the complication. These complications occurred in patients that were operated upon in the earlier part of this series when we were ligating rather than dividing the ductus, and before we were using the posterolateral approach with aortic mobilization and its resultant facile and complete exposure of the recurrent laryngeal nerve. In the earlier ligations of the ductus with two silk umbilical tapes, we did indeed identify the recurrent nerve, but the edema, pressure, and scar tissue as the result of the two knots may well have accounted for permanent damage to the nerve.

Pneumothorax postoperatively has occurred only in the patients in whom the chest was not drained, or in patients with extensive dissection of pleural adhesions and small air leaks resulting therefrom. All were treated by aspiration and none required tube drainage.

Tracheobronchitis was a troublesome complication in 6 patients, all infants or children, but only 1 developed empyema that required tube drainage. All patients eventually responded to appropriate treatment, and, again, all occurred in the earlier group of patients, who may have had inadequate tracheobronchial toilet and no efficient antibiotic therapy.

Chylothorax may be a troublesome complication, although not serious or lethal. Two of 5 patients required thoracotomy and ligation of the leaking radicle of the thoracic duct; neither patient had had the chest drained at the initial operation. Easily identified, these mediastinal oozers were in both cases picked up just at or a little above the takeoff of the left subclavian artery and tied. There were, in both patients, no further

complications. In the remaining 3, 1 responded to multiple thoracentesis, and the other 2, who had already had drainage at the initial thoracotomy, required the tube left in place for 5 and 6 days, respectively, before lymph drainage ceased with complete lung expansion.

Wound infection, including the one empyema, and a miscellaneous assortment of other complications, including heart failure, occurred in 17 patients without fatality. Subacute bacterial infection postoperatively occurred in 4 patients, who are included among the 10 patients having preoperative subacute bacterial endocarditis. They were operated upon without antibiotic treatment and all died following operation as the result of their disease.

Several patients had multiple complications, all of which are tabulated, so that the actual patient incidence of complications is much lower than 10.5 per cent.

Mortality

The mortality statistics for the entire series of 909 operations for patent ductus arteriosus is summarized in Table IX. Among the patients over the age of 1 year with uncomplicated ductus, there were 642 cases with six deaths, a mortality of 0.9 per cent. In the same age group, 122 patients with ductus and accompanying cardiovascular lesion, there were five deaths, a mortality of 4 per cent. In all patients (59) under 1 year of age, with and without other visceral or cardiovascular lesions, there were nine deaths, a surgical mortality of 15 per cent. Among the 25 patients whose patent ductus

Table IX. Mortality

	<i>No. of operations</i>	<i>Deaths (%)</i>	
Divisions			
Uncomplicated ductus	642	6	0.9
Ductus + other lesion	122	5	4.0
Ductus in patient under 1 yr. of age	59	9	15.0
Ductus with pulmonary hypertension	25	9	36.0
Ligations	61	2	3.1
Totals	909	31	3.4

Table X. Last 10 years' experience (1955-1964)*

Year	Operations	Deaths	Age at death	Associated problems
1955	58	3	9 yr. 13 yr. 22 yr.	Subacute bacterial endocarditis Pulmonary hypertension + coarctation Pulmonary hypertension
1956	66	0		
1957	44	2	5 yr. 1 mo.	Ventricular septal defect + renal anomaly Ventricular septal defect + atrial septal defect
1958	50	3	5 wk. 8 mo. 18 mo.	Pulmonary hypertension + coarctation Growth failure Pulmonary hypertension + coarctation
1959	39	1	14 yr.	Ventricular septal defect
1960	35	2	16 yr. 3 wk.	Pulmonary hypertension Pulmonary stenosis + coarctation
1961	38	2	8 mo. 2 mo.	Ventricular septal defect Pulmonary valvular atresia
1962	32	0		
1963	32	1	5 wk.	Coarctation + ventricular septal defect
1964	37	2	1 mo. 2 wk.	Coarctation No associated lesion
Totals	431	16		

*431 Operations; one death in a patient with an uncomplicated ductus (mortality = 0.2 per cent).

was complicated by pulmonary hypertension, there were nine deaths, a mortality of 36 per cent.

There were two deaths in 61 ligations of patent ductus arteriosus (3.1 per cent mortality), over threefold the mortality of the division and suture group. More important, the morbidity and complications among the ligations were exceedingly high in proportion to the division group.

In the last 10 years (1955-1964), there were 431 divisions of the patent ductus with sixteen deaths (Table X), a mortality of 3.6 per cent. Fifteen of these deaths were in patients having other superimposed complicating cardiovascular or visceral lesions. There has been only one death in all of the uncomplicated cases of ductus, including all ages, in the last 10 years, a mortality of 0.2 per cent.

Summary

I believe that in all cases of patent ductus arteriosus the ductus should be divided and not ligated.

The techniques presented are feasible and safe in the vast majority of the problems encountered in the surgery of the ductus.

Surgery at an earlier age may prevent many of the catastrophes that result from the vascular changes of pulmonary hypertension that begin in the first few years of life.

The constant awareness of the potential presence of bacterial blood stream infection in all patients being prepared for surgery of the ductus and coarctation of aorta will avoid grave morbidity and mortality from subacute bacterial endocarditis and mycotic aneurysm. These are ever with us in spite of the availability of potent antibiotic therapy.

I have presented my 25 years' experience and given you the data on all of the complications and pitfalls that are inherent in an operation which to the inexperienced surgeon may appear to be simple and straightforward, at least in the uncomplicated ductus.